

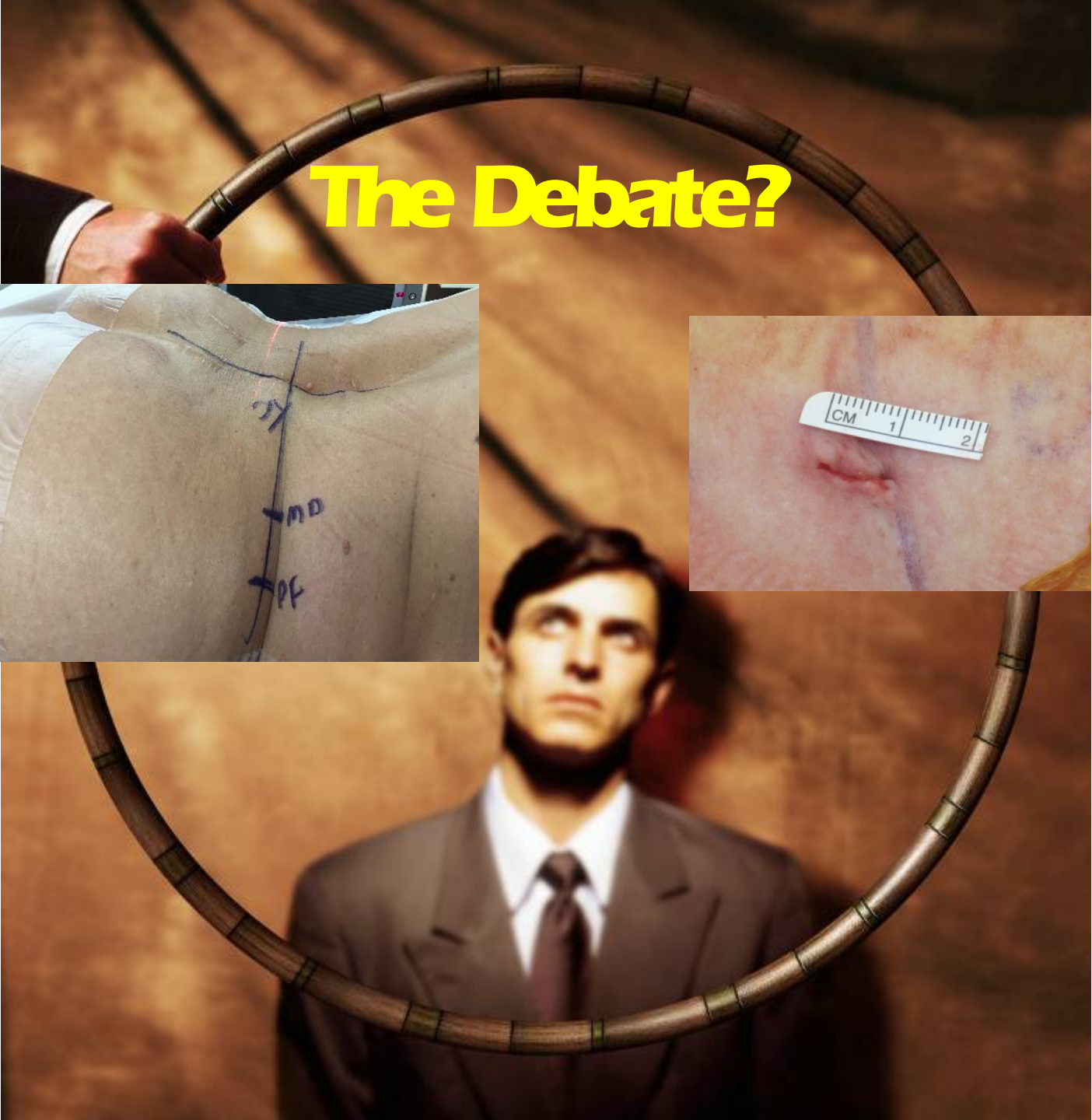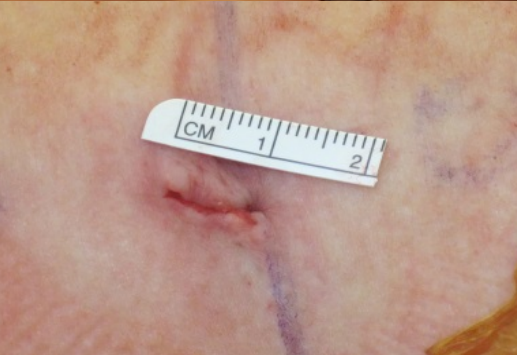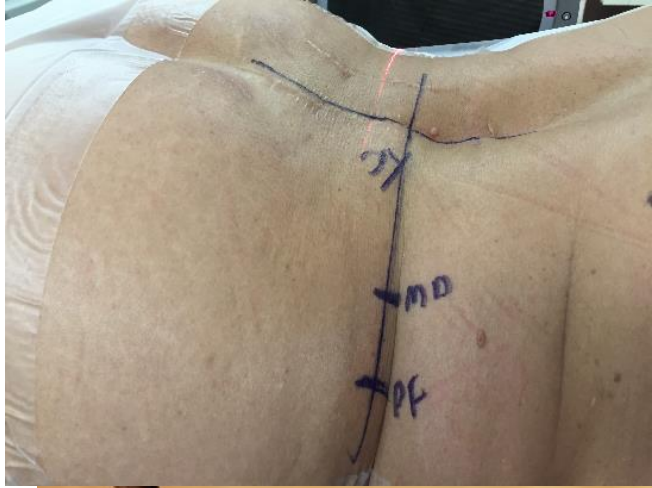L5-S1 Right Sided Endoscopic  
Laser Assisted Foraminoplasty  
after Acquired Stenosis  
Following Routine Discectomy

James J. Yue, M.D.

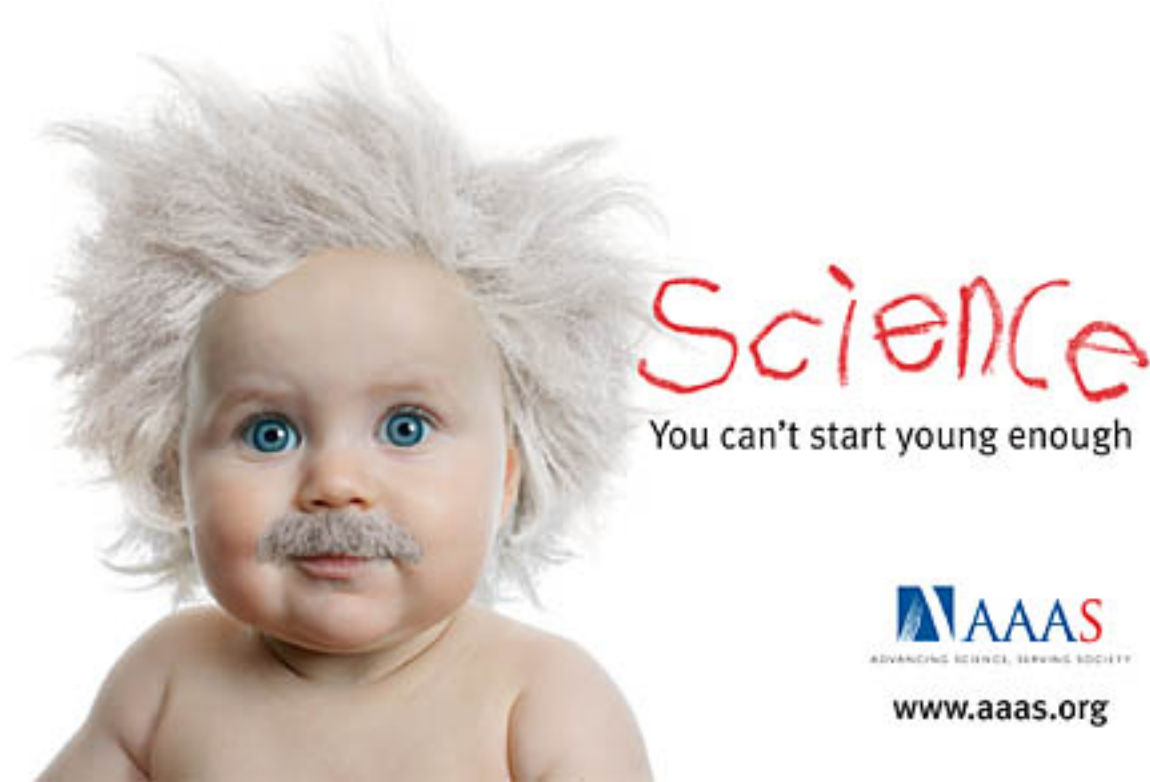[www.jamesyue.com](http://www.jamesyue.com)

[jamesyue65@gmail.com](mailto:jamesyue65@gmail.com)

# The Debate?



# Distinguished, Esteemed, and Respected Colleague

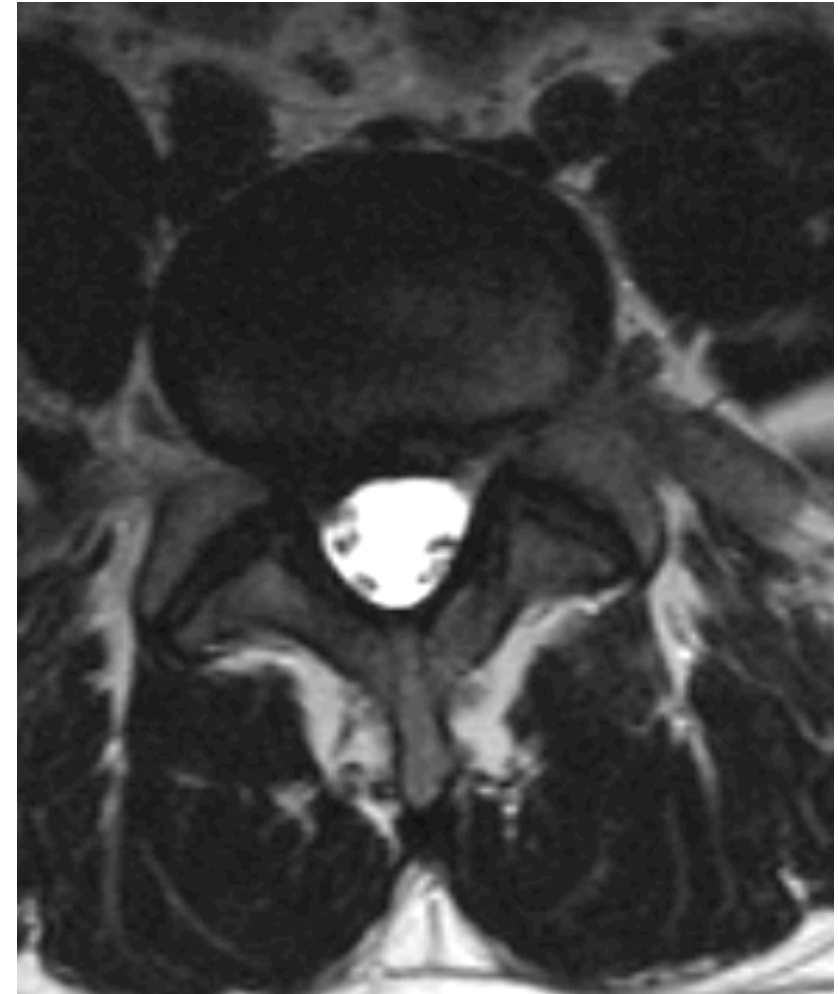
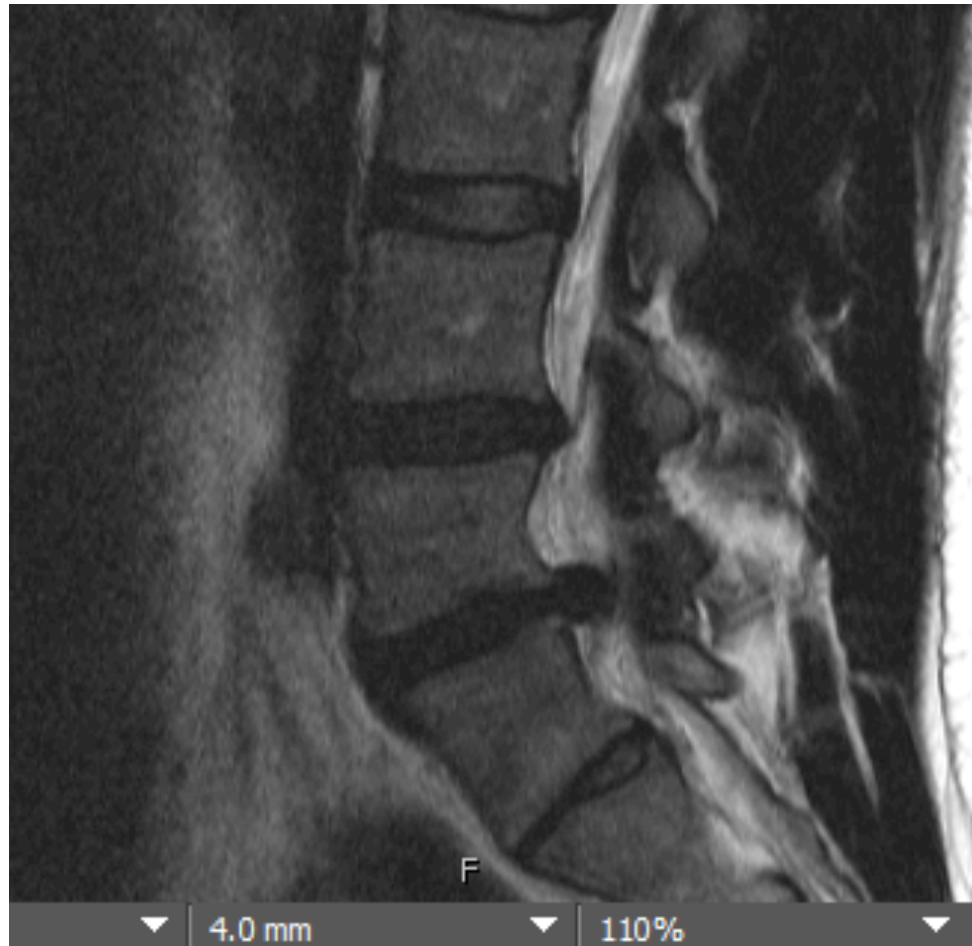

[www.aaas.org](http://www.aaas.org)

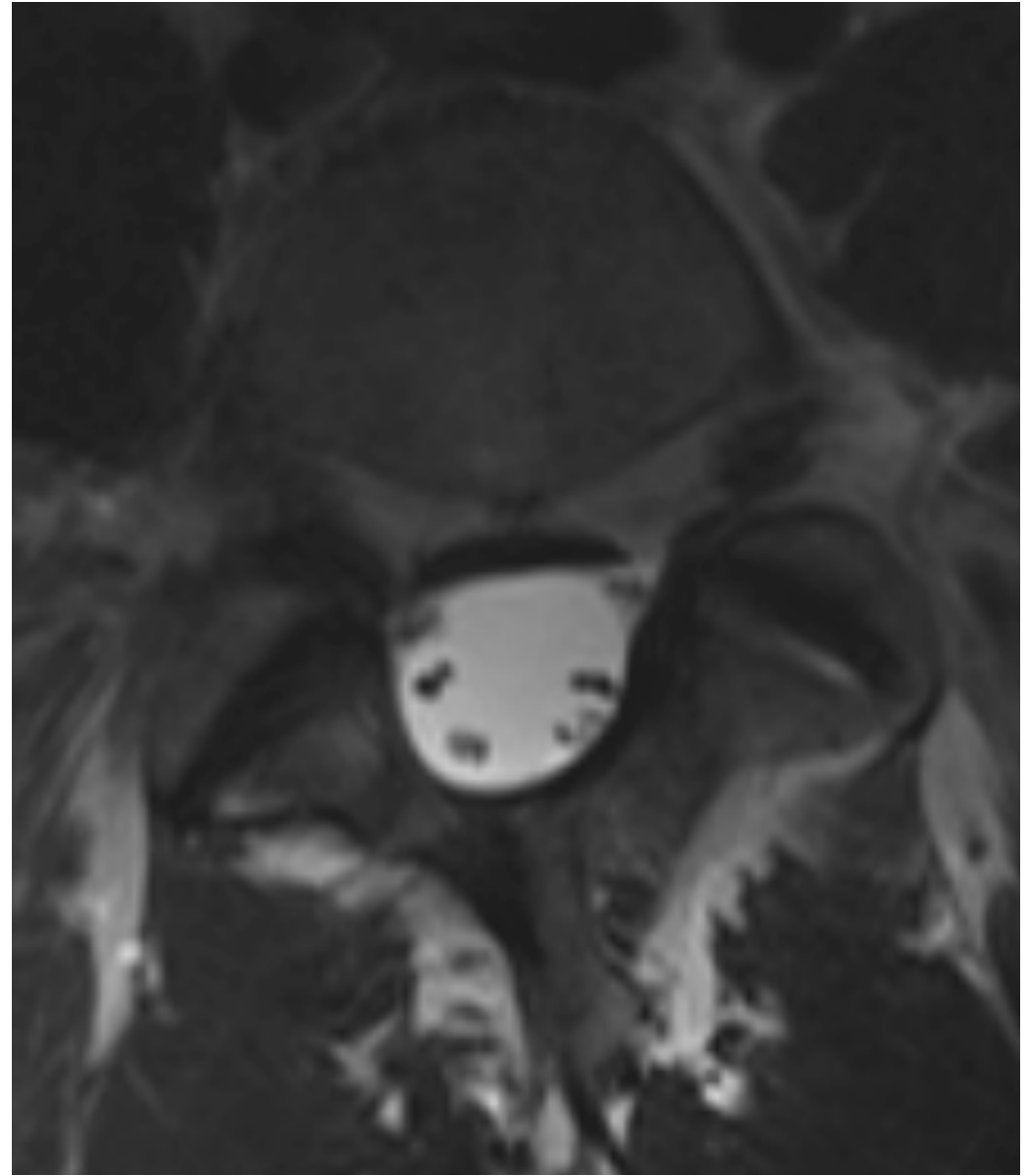
# History and Physical

- 34 yo male who underwent successful prior L5-S1 right sided discectomy for S1 radiculopathy
- 3 years after discectomy he had gradual onset of L5 radiculopathy
- SNRB right side with temporary relief of leg pain
- Computer science engineering
- Large family
- + SLT 40 degrees right
- EHL 4/5 especially after ambulating
- + numbness L5 dorsal foot and lateral calf
- Gluteal pain right sided

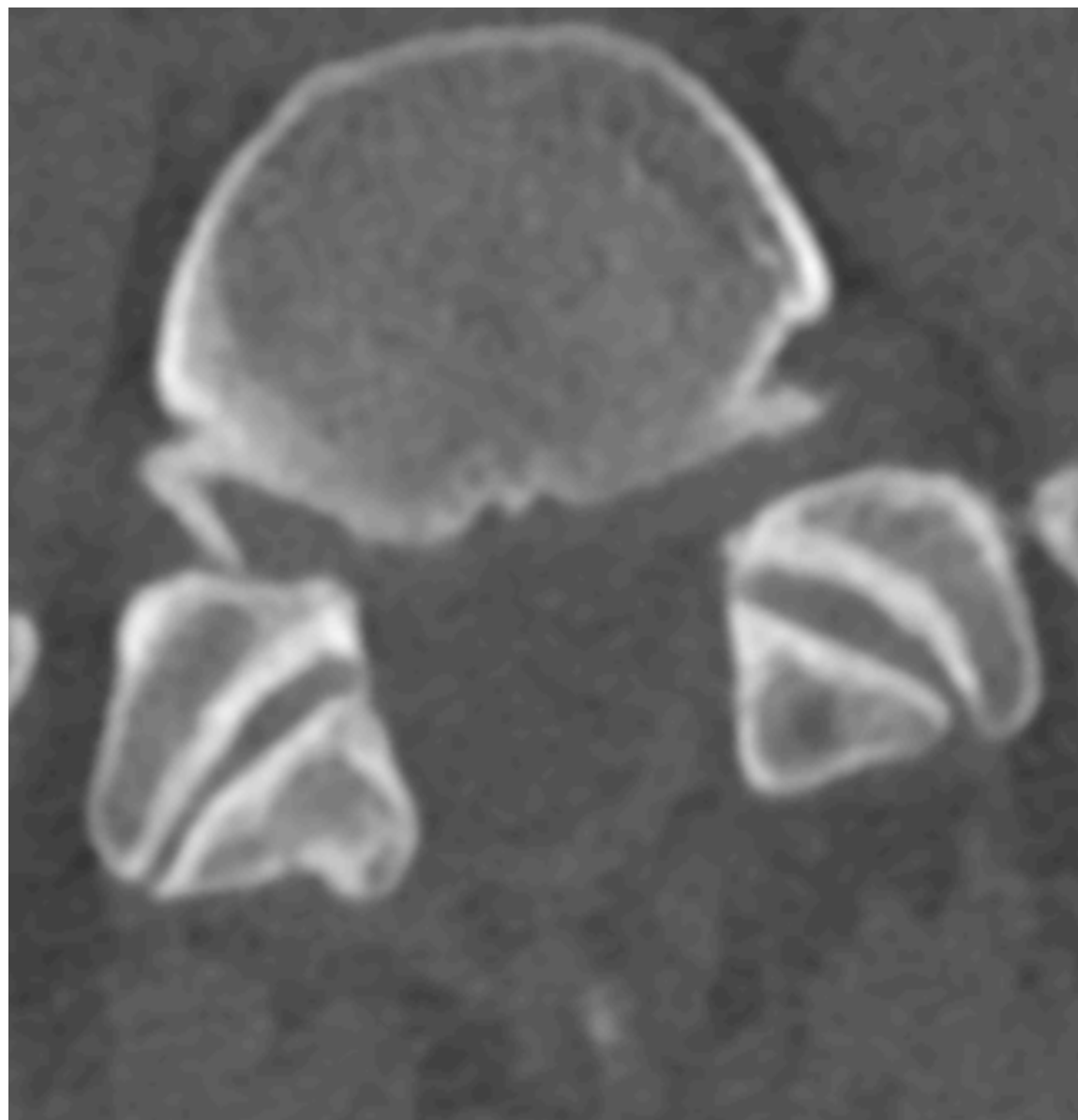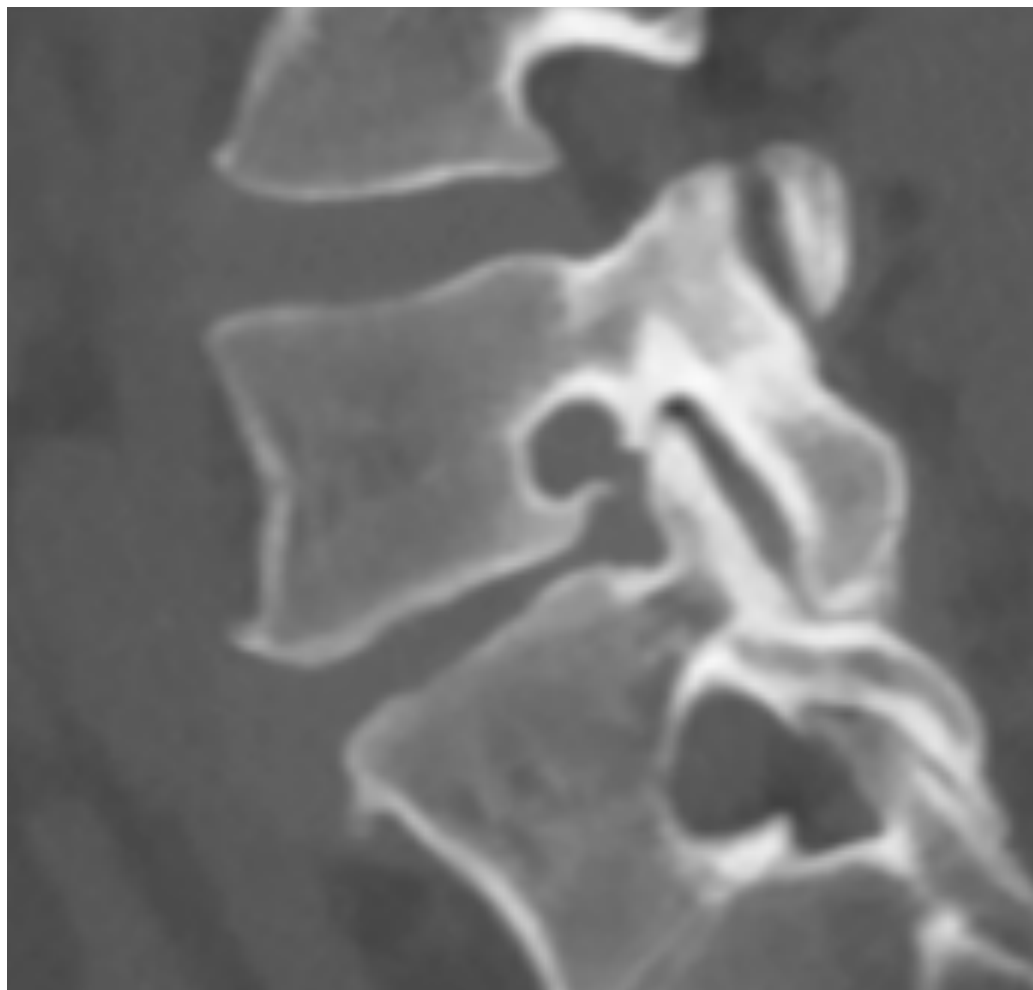
# Pre-op Prior to L5-S1 Discectomy 2015



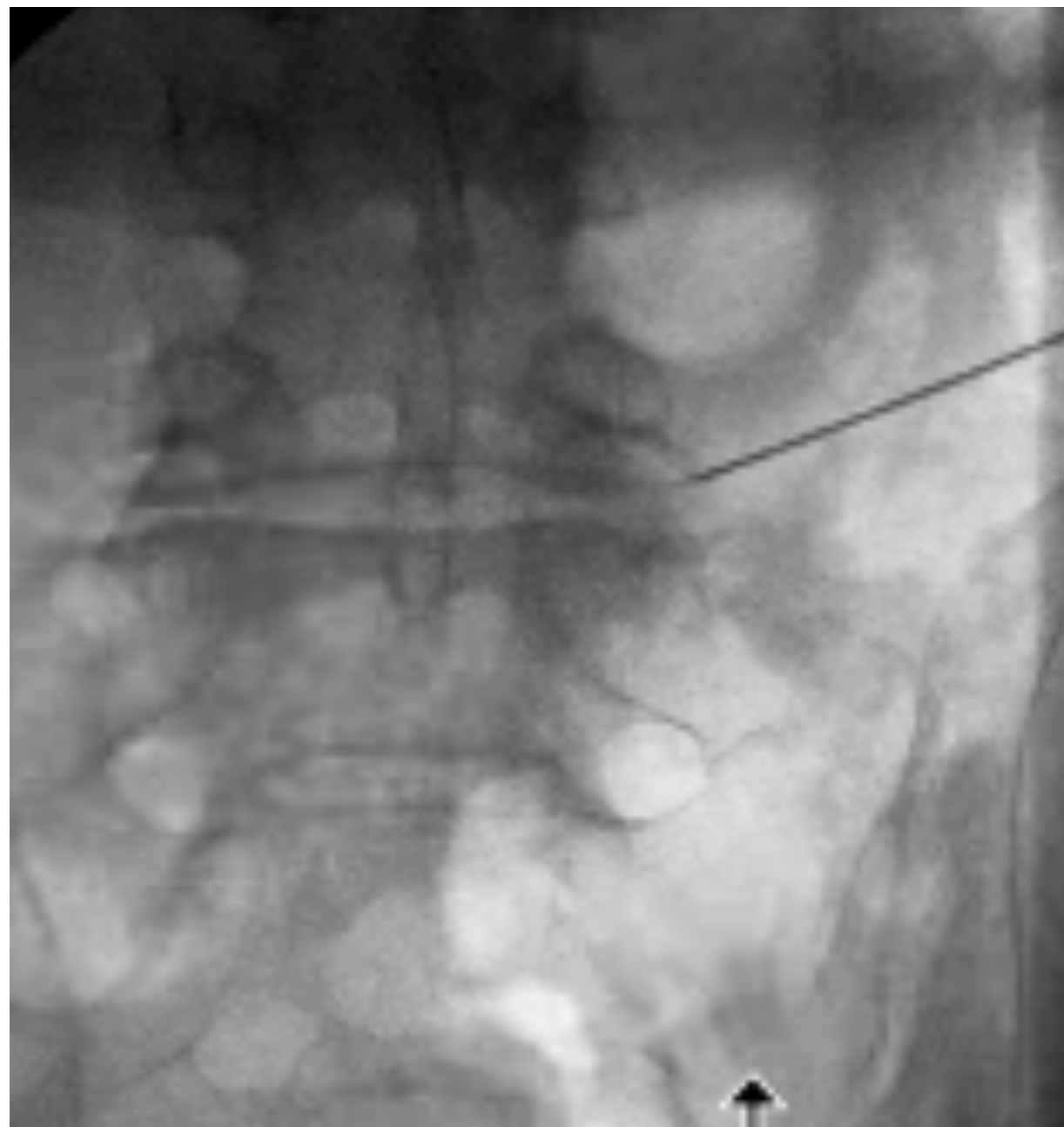
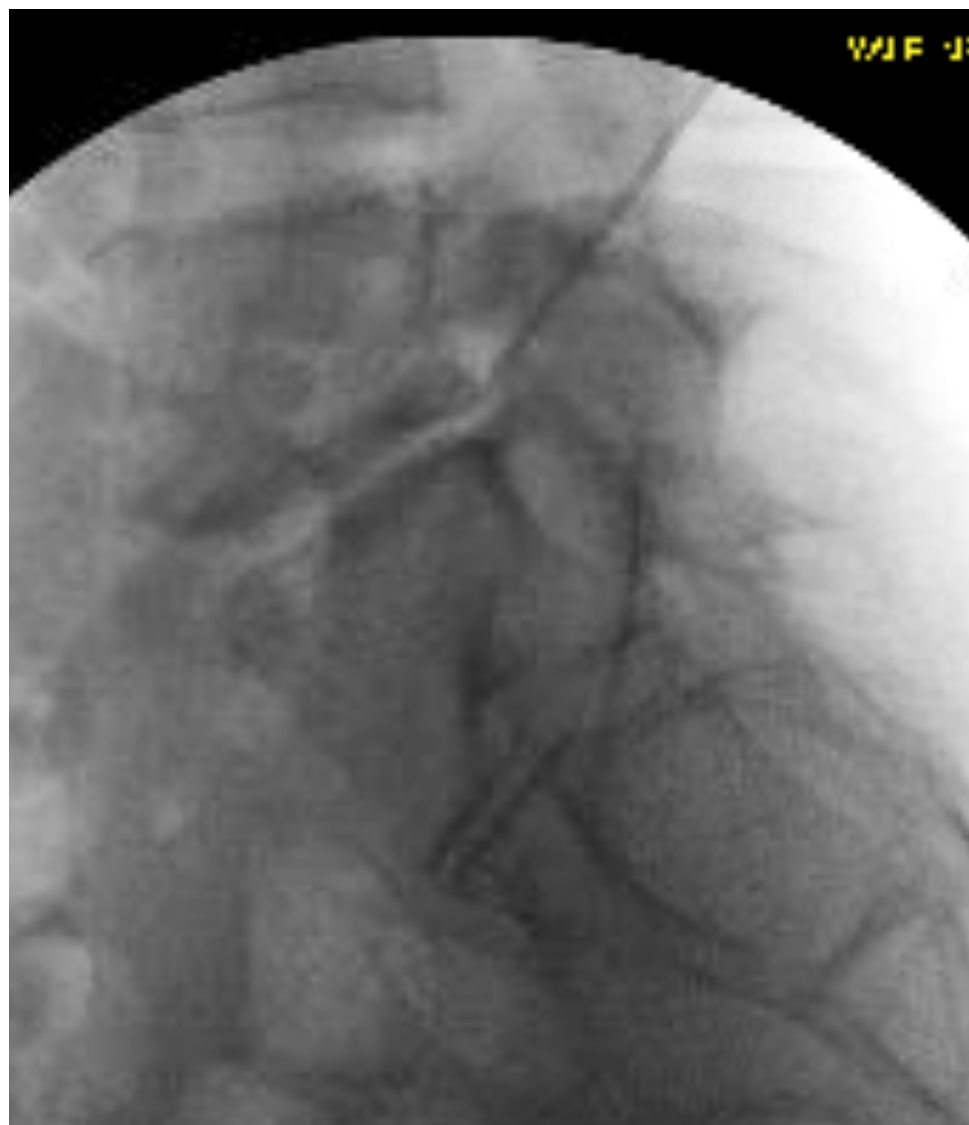Pre-op 2018



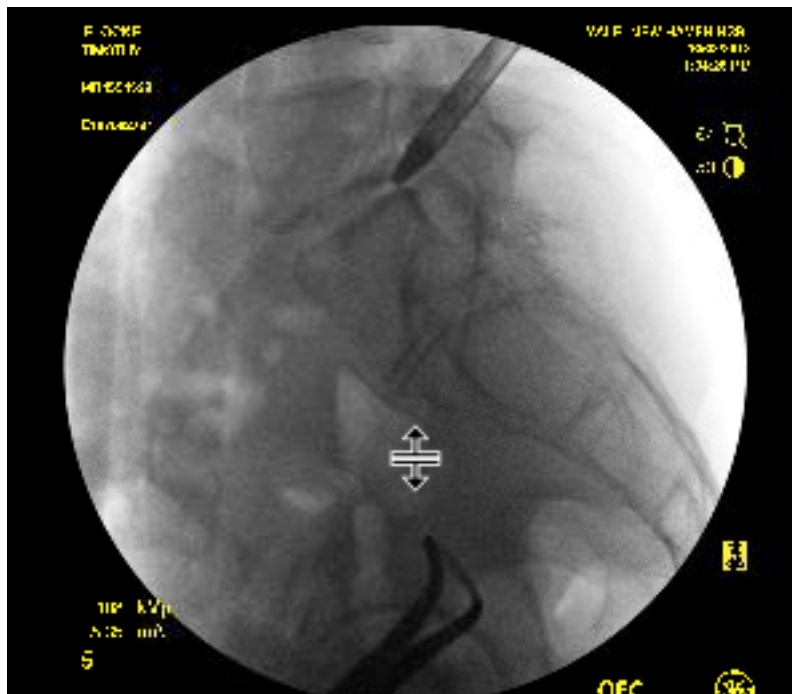
Pre-op 2018













James J. Yue, M.D.

[www.jamesyue.com](http://www.jamesyue.com)

[jamesyue65@gmail.com](mailto:jamesyue65@gmail.com)